12. ULUSAL JİNEKOLOJİ ve OBSTETRİK KONGRESİ

6. AKDENİZ ÜLKELERİ JİNEKOLOJİ ve OBSTETRİK FEDERASYONU KONGRESİ

15 - 19 MAYIS 2014

RIXOS SUNGATE OTEL, ANTALYA

KANUNİ SULTAN SÜLEYMAN EĞİTİM ve ARAŞTIRMA HASTANESİ

PLASENTA ADEZYON BOZUKLUKLARI

Dr. İbrahim POLAT

Kadın Hastalıkları ve Doğum-Perinatoloji

Plasenta Adezyon Bozuklukları / Anormal İnvazif Plasenta / Plasenta Akreta

Plasentanın myometriuma değişik derecelerde anormal olarak yapışması

- **Akreta %79**

  Koryonik villuslar (desidua basalisin içinde sınırlı kalmaktan çok) myometriyuma yapışmıştır

- **İnkreta %14**

  Koryonik villuslar myometriyumun içine invaze olmuştur

- **Perkreta %7**

  Koryonik villuslar myometriyumun dışına doğru, serozaya kadar penetre olmuştur.

(Anath CV 1997)

SIKLIK

50 yıl önce de nadir bir durumdu, günümüzde daha sık görülmektedir

- 1950'lerde.....**30.000** doğumda 1 (Read JA 1980, Miller DA 1997)
- 1980 lerde..... **2.510** doğumda 1 (Read JA 1980, Miller DA 1997)
- 1982-2002..... **533** doğumda 1 (Wu S 2005)

- Artışın asıl nedeni: SEZARYEN SAYISI ARTIŞI
- 2000 yılından sonra artış C/S artış oranından fazla **(Higgins MF, 2013)**

ÖNEMİ

- **MATERNAL MORBİDİTE ve MORTALİTE'nin** en önemli nedenlerinden
- % 7 mortalite bildirilmektedir (O'brein JM 1996)
- Peripartum kanama ve Plasentanın doğurtulması sırasında **aşırı kanama riski var**
- **Histerektomi** sıklıkla gerekir
- **Mesane, üreter ve barsak yaralanma riski var**
- **Yoğun bakım** gereksinimi artar

The Journal of Obstetrics and Gynecology of India (January–February 2012) 62(1):57–61
DOI 10.1007/s13224-012-0149-5

ORIGINAL ARTICLE

Morbidly Adherent Placenta: A Critical Review

Aggarwal Richa · Suneja Amita · Vaid Neelam Bala ·

Abstract

Objective To evaluate the demographic profile, high risk factors, fetomaternal outcome and management options in morbidly adherent placenta (MAP).

Study Design Retrospective analysis.

Methodology Review of 20 case records of women with MAP during year 2001–2006.

Results The mean age and parity of the women was 27.7 ± 4.2 years and 2.5 respectively. 70 % women had previous uterine scar, and similar number had placenta previa. 60 % women presented with antepartum hemorrhage and 20 % with retained placenta. 85 % women underwent hysterectomy with 5 % requiring internal iliac artery ligation, another 5 % partial cystectomy and 15 % bladder repair. Blood loss was between one and nine litres requiring an average of six units whole blood and 4 units FFP. There were six (30 %) maternal deaths. 55 % of the newborns were preterm and the perinatal mortality was 33.3 %.

20 PA olgusu (%60 kanamalı)

%85 histerektomi

%30 maternal ölüm

%33,3 perinatal mortalite

AOGS
ACTA Obstetricia et Gynecologica Scandinavica

AOGS SHORT RESEARCH REPORT

Abnormally invasive placenta: changing trends in diagnosis and management

KIRAN GULERIA, BINDIYA GUPTA, SHUCHI AGARWAL, AMITA SUNEJA, NEELAM VAID & SANDHYA JAIN

Department of Obstetrics and Gynecology, University College of Medical Science and Guru Teg Bahadur Hospital, Delhi, India

Abstract

Acta Obstetricia et Gynecologica Scandinavica © 2013

Trends in patient profile, clinical presentation, diagnosis, management options and outcome of abnormally invasive placenta (AIP) were retrospectively evaluated at a tertiary care centre from 2001 to 2010. AIP was diagnosed when confirmed by ultrasound or MRI, when complete manual removal of placenta was not possible or when histological confirmation was achieved in a hysterectomy specimen. The first and second halves of the time period were compared. The total number of cases was 56 and the incidence increased significantly in the second half. Main risk factors were placenta previa and previous cesarean section. Antenatal diagnosis by ultrasound was made in 72% in the second half, compared with 35% in the first half ($p = 0.009$). Maternal mortality was 29% in the first half and 21% in the second half. Hysterectomy was the mainstay in management; elective procedures being significantly higher in the second half.

postnatal, admitted to the obstetrics ward of the University College of Medical Sciences and Guru Teg Bahadur Hospital, Delhi, India, a tertiary care referral centre, from Octo-

To evaluate the changing trends we compared the first and second halves of the 9-year time period and divided it into Period A and Period B. The number of women was 17 and 39 in the two groups, respectively. Data

Table 1. Patient characteristics and clinical presentation.

	Period A (n = 17)	%	Period B (n = 39)	%	p-value
Age (years)	27 ± 4.2		27 ± 2.83		0.82
Parity	2 ± 0.9		3 ± 1.20		0.02
Multiple pregnancy	0		1		
Booking status					
Booked	3	18.7	23	59	0.0006
Unbooked	14	82.3	16	41	
Gestational age at delivery (weeks)	35.2 ± 3.2		35.5 ± 3.5		0.72
Retained placenta	2		3		0.32
Type of delivery					
Vaginal	3	17.5	3	8	
Elective cesarean section	3	17.5	24	60	0.01
Emergency cesarean section	11	65	12	32	

Table 2. Maternal morbidity and mortality.

	Period A (n = 17)	Period B (n = 39)
Bladder injury	3	3
Disseminated intravascular coagulation	12	14
Infection	6	6
Burst abdomen	–	1
Intensive care unit transfer	10	12
Maternal mortality, n (%)	5 (29)	8 (20.5)

Etyoloji -Patogenez

- **Kesin olarak bilinmemektedir.** Teoriler var:
  - **Defektif desidualizasyon (en yaygın teori)** (Khong TY 2005)
  - Aşırı ekstravillöz trofoblastik invazyon (Tantbirojn P 2008)
  - Histerotomi skarında defektif vasküler remodeling (Jauniaux E, 2012)
- **Patolojik invazyon derinliğini belirleyen faktörler de bilinmemektedir**

Risk Faktörleri

- **Plasenta Previa (OR=54)**
- **Geçirilmiş uterin cerrahi**
- Maternal yaş
- Multiparite
- Uterin küretaj
- Uterin radyasyon
- Endometrial ablasyon
- Asherman sendromu
- Myom
- Uterin anomaliler
- Sigara
- IVF gebelikler
- Hipertansif hastalıklar

EN ÖNEMLİ RİSK FAKTÖRÜ: **C/S SONRASI PLASENTA PREVİA**

	PP + %	PP - %
C/S yok	1-5	
Eski 1 C/S	11-25	0,3
Eski 2 C/S	35-47	0,6
Eski 3 C/S	40	2,4
Eski 4 ve üzeri C/S	50-67	

NIH Consensus Development Conference, March 8-10, 2010

Frequency of placenta accreta according to number of cesarean deliveries and presence or absence of placenta previa[11]

Cesarean delivery	Placenta previa	No placenta previa
First (primary)	3.3	0.03
Second	11	0.2
Third	40	0.1
Fourth	61	0.8
Fifth	67	0.8
≥Sixth	67	4.7

SMFM. Placenta accreta. Am J Obstet Gynecol 2010.

C/S sayısı arttıkça pl akreta sıklığı da artar, ama PP olmayanlarda sayı çok daha azdır

Primer-elektif C/Slarda PA gelişmesi daha fazla (3 kat)

(Kamara M, BJOG 2013)

Tanı - ultrasonografi

- Tanı genellikle II veya III. trimesterde USG ile konulur
- I. trimesterde akreta tanısında rutin olarak kullanılmamalı ?
- Ancak, bazı bulgular akreta riskini artırır:
  - Plasental yatakta çok sayıda düzensiz vasküler boşluklar
  - Alt uterin segmente yerleşmiş gebelik kesesi
  - SSG

ULTRASOUND
in Obstetrics & Gynecology

VOLUME 43, ISSUE 4, PAGES
383–395, APRİL 2014

Cesarean scar pregnancy and early placenta accreta share common histology

I. E. Timor-Tritsch

- 29 **SSG ve Erken Plasenta Akreta** (EPA) histolojisi incelenmiş
- **Histopatolojik bulgular aynı**
- **Aynı hastalığın (III trim PA)..... farklı evreleri** olabilir

A

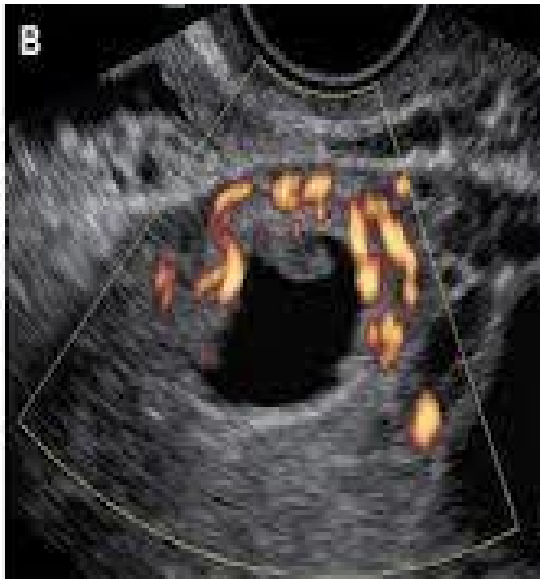
B

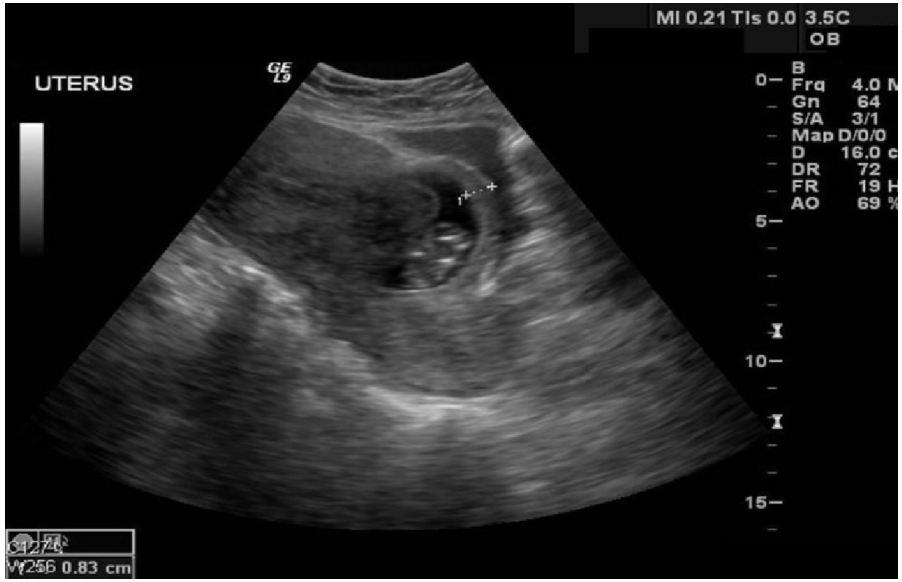
MI 0.21 TIs 0.0 3.5C
OB
UTERUS
B
Frq 4.0 M
Gn 64
S/A 3/1
Map D/0/0
D 16.0 c
DR 72
FR 19 H
AO 69 %
0
5
10
15
W256 0.83 cm

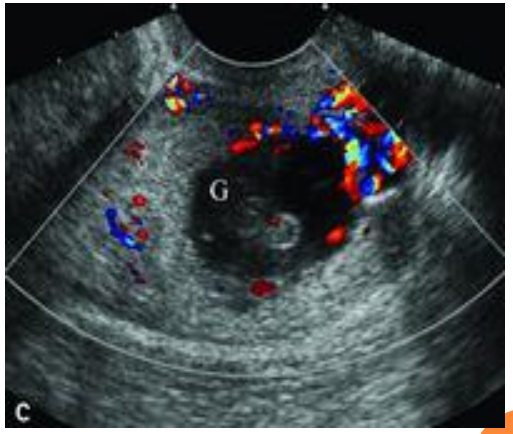
G
C

Tanı

Ultrasonografi (TA-TV) ve renkli doppler

1. **Retroplasental hipoekoik zonun kaybı**
2. Plasentada **multipl vaskuler lakün** (sensitivite %80-90)
3. **Myometrium-mesane ara yüzünde** olan veya **uterin serozayı geçen damarlar**
4. **Retroplasental myometrial kalınlık < 1mm**
5. **3-D power Doppler'de çok sayıda damar**
6. Uterus seroza -mesane duvarı ara yüzünü gösteren **beyaz çizginin kaybı veya kesikleşmesi (mesane invazyonu)**

- İlk trimesterde **skar gebeliği** veya **aşağı uterus implantasyonlu gebelik**

(Abuhmad a, 2013)

OZCAN, BIRGUL PREVIA TOTALIS
IC 5-9H/OB
MI 1.2
KSS-EAH PERINATOLOJI
41176-13-09-18-19 GA=36w6d
8.9cm / 20Hz
TIs 0.2
23.09.2013 12:03:53
Penetration
9.00 - 2.00
Pwr 100
Gn -3
C7 / M5
P3 / E2
SRI II 3
IO
EO
FH
PL

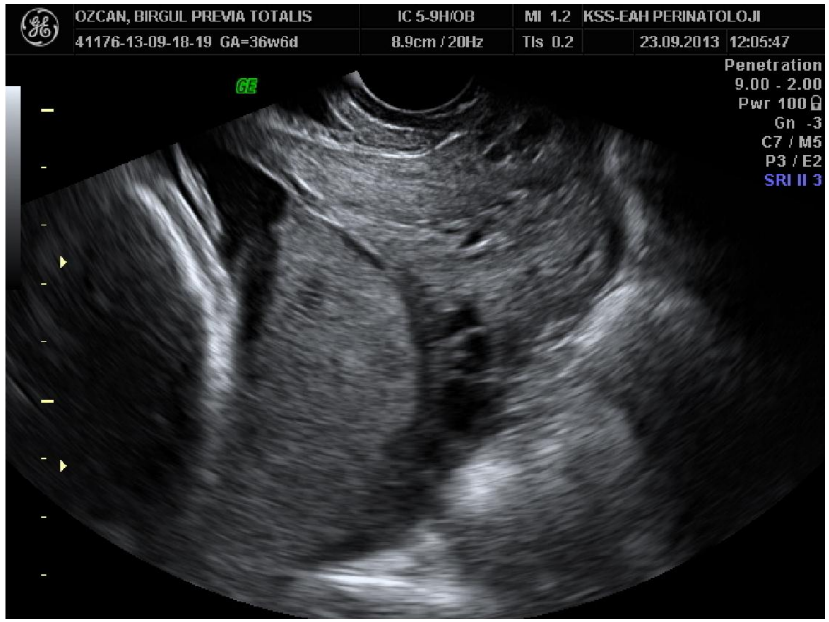
OZCAN, BIRGUL PREVIA TOTALIS
IC 5-9H/OB
MI 1.2
KSS-EAH PERINATOLOJI
41176-13-09-18-19 GA=36w6d
8.9cm / 20Hz
TIs 0.2
23.09.2013 12:05:47
Penetration
9.00 - 2.00
Pwr 100
Gn -3
C7 / M5
P3 / E2
SRI II 3

ucar, latife
IC 5-9H/OB
MI 1.2
KSS-EAH PERINATOLOJI
41176-13-10-24-1 GA=28w3d
12.5cm / 21Hz
TIs 0.2
24.10.2013 00:47:45
Penetration
9.00 - 2.00
Pwr 100
Gn -3
C7 / M5
P3 / E2
SRI II 3

ucar, latife
IC 5-9H/OB
MI 1.2
KSS-EAH PERINATOLOJI
41176-13-10-24-1 GA=28w3d
12.5cm / 21Hz
TIs 0.2
24.10.2013 00:47:23
Penetration
9.00 - 2.00
Pwr 100
Gn -3
C7 / M5
P3 / E2
SRI II 3

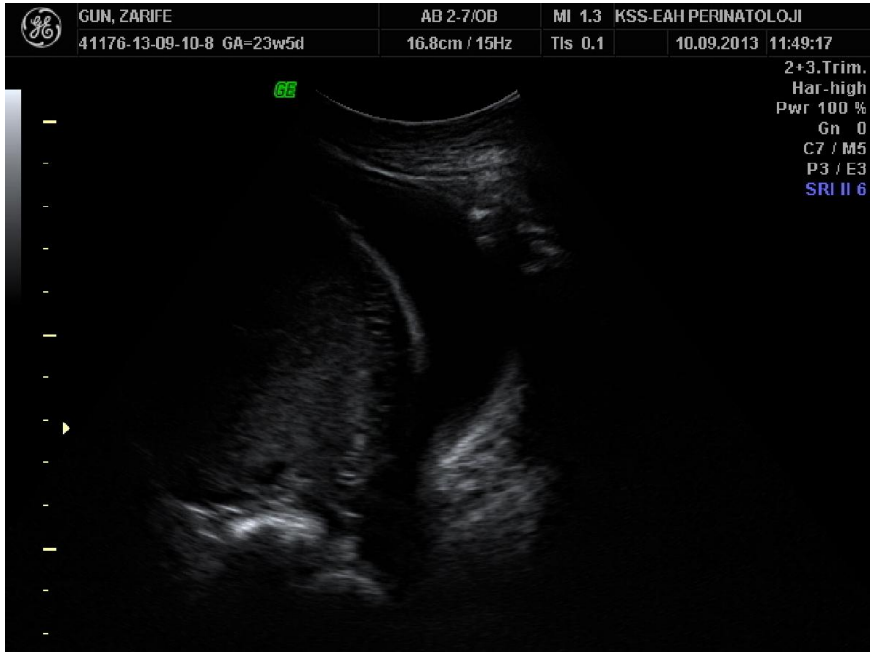
GUN, ZARIFE
AB 2-7/OB
MI 1.3
KSS-EAH PERINATOLOJI
41176-13-09-10-8 GA=23w5d
16.8cm / 15Hz
TIs 0.1
10.09.2013
11:49:17
2+3.Trim.
Har-high
Pwr 100 %
Gn 0
C7 / M5
P3 / E3
SRI II 6

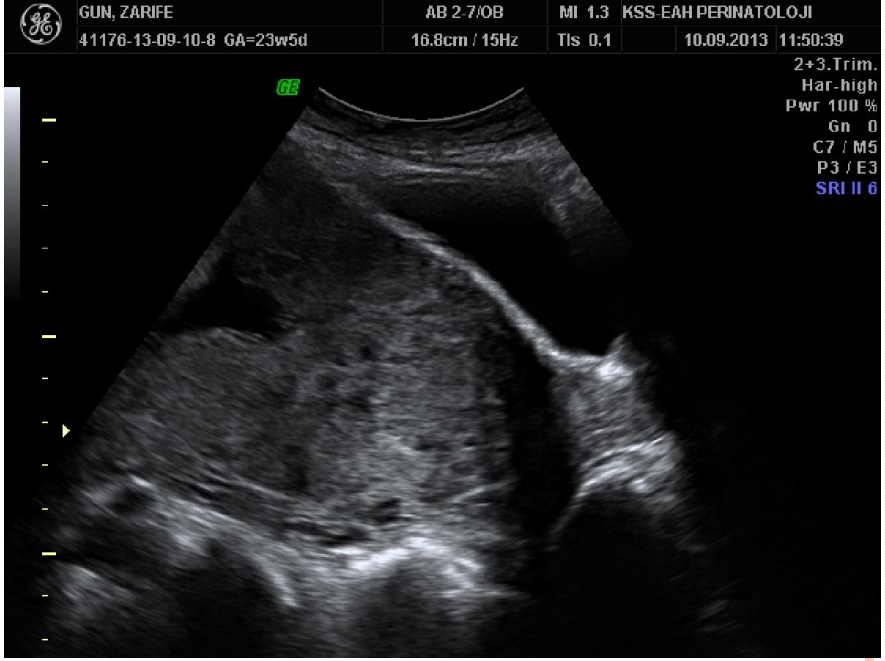
GUN, ZARIFE
AB 2-7/OB
MI 1.3
KSS-EAH PERINATOLOJI
41176-13-09-10-8 GA=23w5d
16.8cm / 15Hz
TIs 0.1
10.09.2013
11:50:39
2+3.Trim.
Har-high
Pwr 100 %
Gn 0
C7 / M5
P3 / E3
SRI II 6

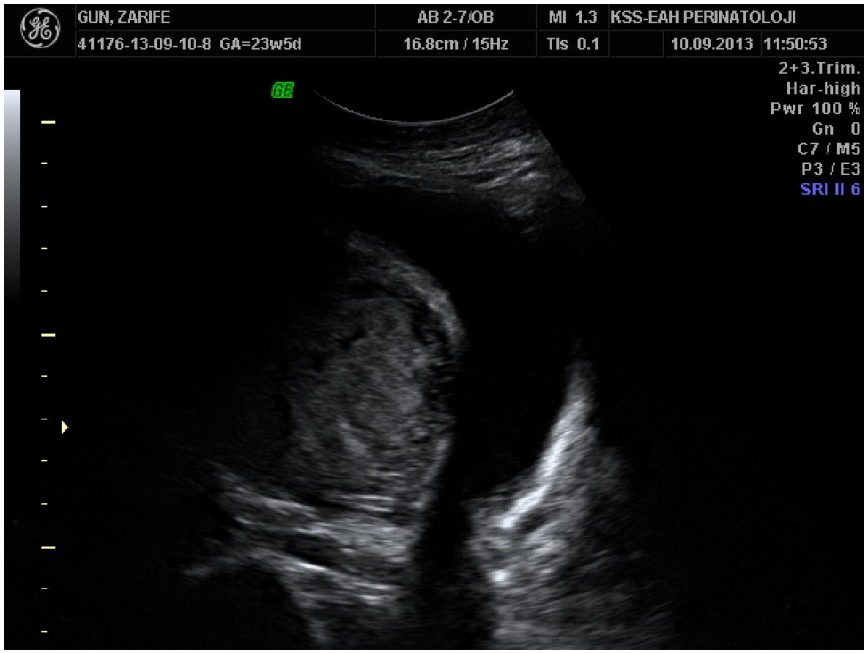
GUN, ZARIFE
AB 2-7/OB
MI 1.3
KSS-EAH PERINATOLOJI
41176-13-09-10-8 GA=23w5d
16.8cm / 15Hz
TIs 0.1
10.09.2013
11:50:53
2+3.Trim.
Har-high
Pwr 100 %
Gn 0
C7 / M5
P3 / E3
SRI II 6

endeza, filiz
AB 2-7/OB
MI 1.3
KSS-EAH PERINATOLOJI
41176-13-07-08-6 GA=36w0d
16.8cm / 15Hz
TIs 0.1
08.07.2013 10:27:39
2+3.Trim.
Har-high
Pwr 100 %
Gn 0
C7 / M5
P3 / E3
SRI II 6

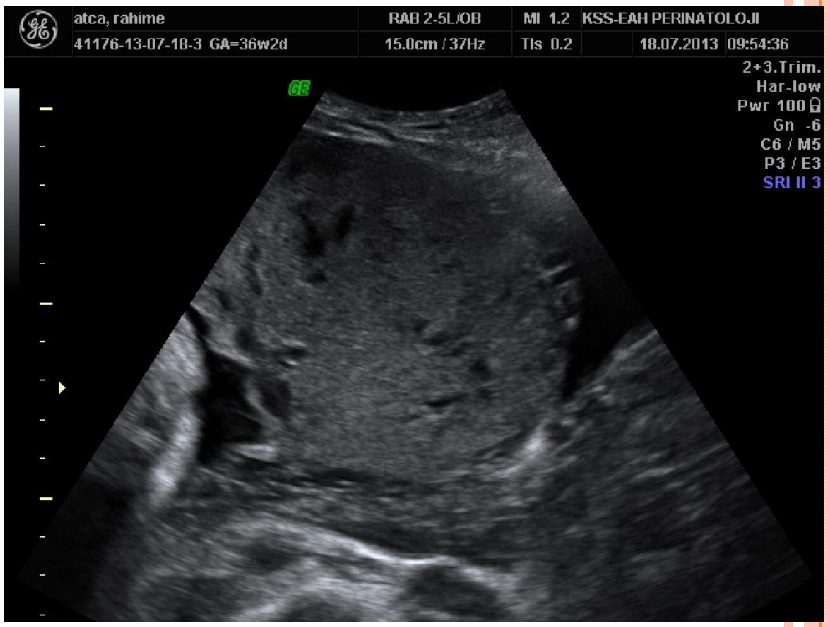
atca, rahime
RAB 2-5L/OB
MI 1.2
KSS-EAH PERINATOLOJI
41176-13-07-18-3 GA=36w2d
15.0cm / 37Hz
TIs 0.2
18.07.2013 09:54:36
2+3.Trim.
Har-low
Pwr 100
Gn -6
C6 / M5
P3 / E3
SRI II 3

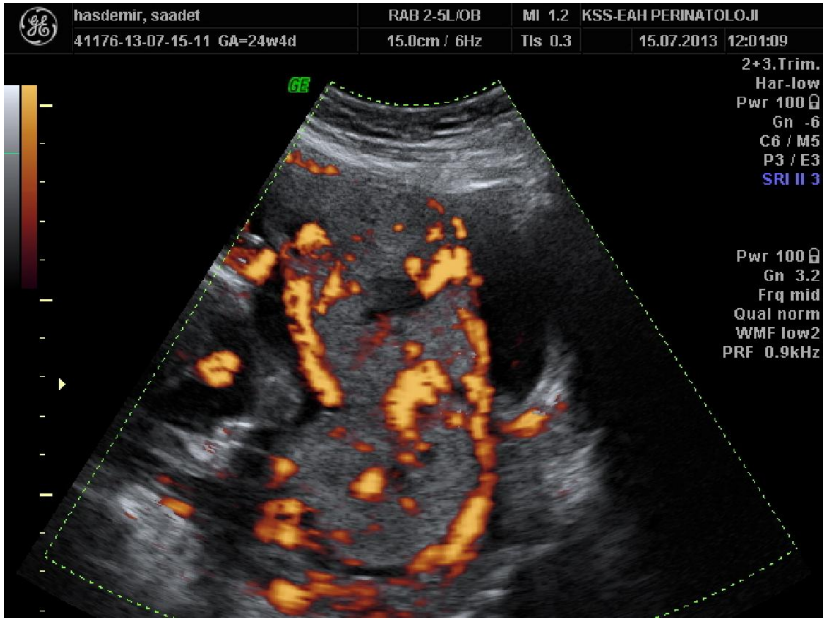
hasdemir, saadet
RAB 2-5L/OB
MI 1.2
KSS-EAH PERINATOLOJI
41176-13-07-15-11 GA=24w4d
15.0cm / 6Hz
TIs 0.3
15.07.2013 12:01:09
2+3.Trim.
Har-low
Pwr 100
Gn -6
C6 / M5
P3 / E3
SRI II 3
Pwr 100
Gn 3.2
Frq mid
Qual norm
WMF low2
PRF 0.9kHz

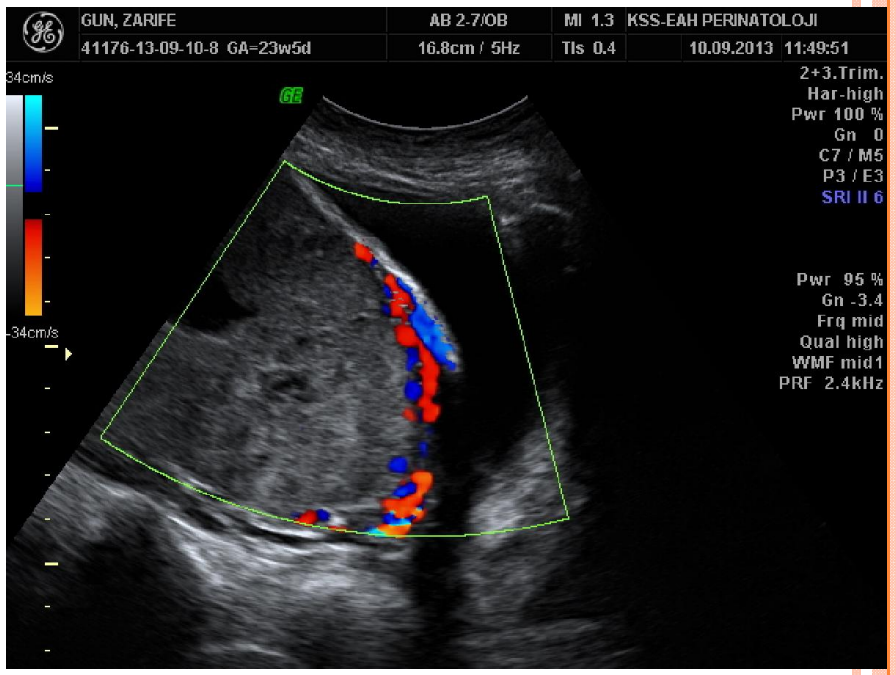
GUN, ZARIFE
AB 2-7/OB
MI 1.3
KSS-EAH PERINATOLOJI
41176-13-09-10-8 GA=23w5d
16.8cm / 5Hz
TIs 0.4
10.09.2013 11:49:51
34cm/s
-34cm/s
2+3.Trim.
Har-high
Pwr 100 %
Gn 0
C7 / M5
P3 / E3
SRI II 6
Pwr 95 %
Gn -3.4
Frq mid
Qual high
WMF mid1
PRF 2.4kHz

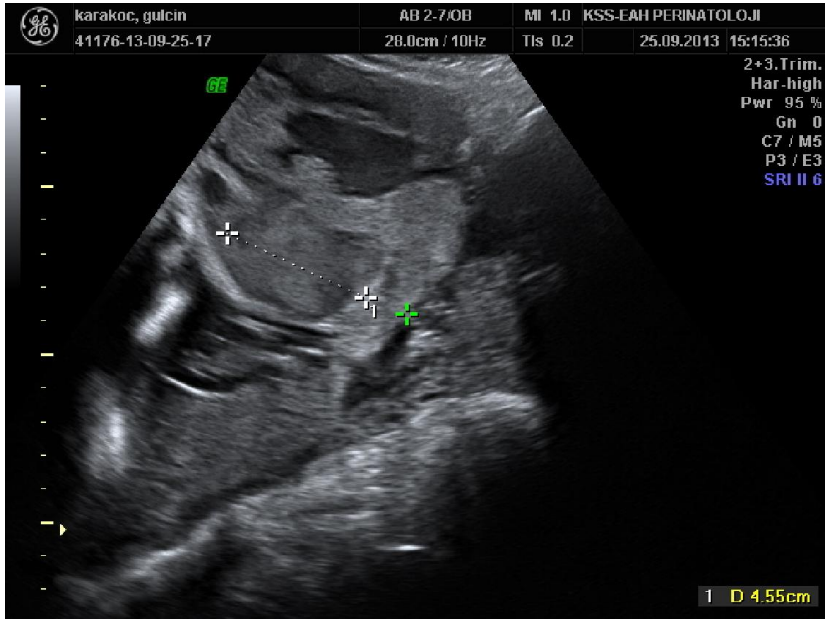
karakoc, gulcin
AB 2-7/OB
MI 1.0
KSS-EAH PERINATOLOJI
41176-13-09-25-17
28.0cm / 10Hz
TIs 0.2
25.09.2013
15:15:36
2+3.Trim.
Har-high
Pwr 95 %
Gn 0
C7 / M5
P3 / E3
SRI II 6
1 D 4.55cm

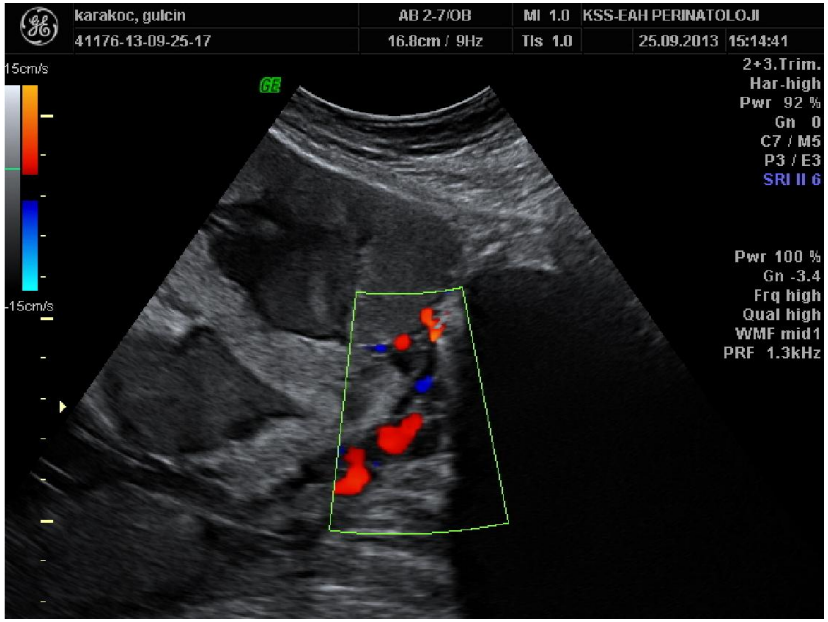
karakoc, gulcin
AB 2-7/OB
MI 1.0
KSS-EAH PERINATOLOJI
41176-13-09-25-17
16.8cm / 9Hz
TIs 1.0
25.09.2013
15:14:41
15cm/s
-15cm/s
2+3.Trim.
Har-high
Pwr 92 %
Gn 0
C7 / M5
P3 / E3
SRI II 6
Pwr 100 %
Gn -3.4
Frq high
Qual high
WMF mid1
PRF 1.3kHz

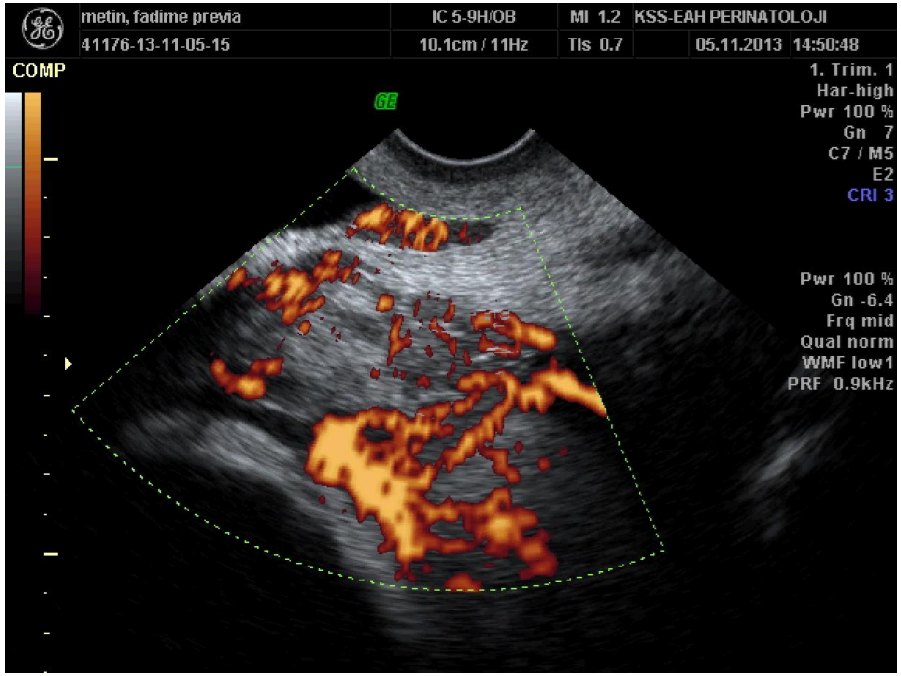
metin, fadime previa
IC 5-9H/OB
MI 1.2
KSS-EAH PERINATOLOJI
41176-13-11-05-15
10.1cm / 11Hz
TIs 0.7
05.11.2013
14:50:48
COMP
1. Trim. 1
Har-high
Pwr 100 %
Gn 7
C7 / M5
E2
CRI 3
Pwr 100 %
Gn -6.4
Frq mid
Qual norm
WMF low1
PRF 0.9kHz

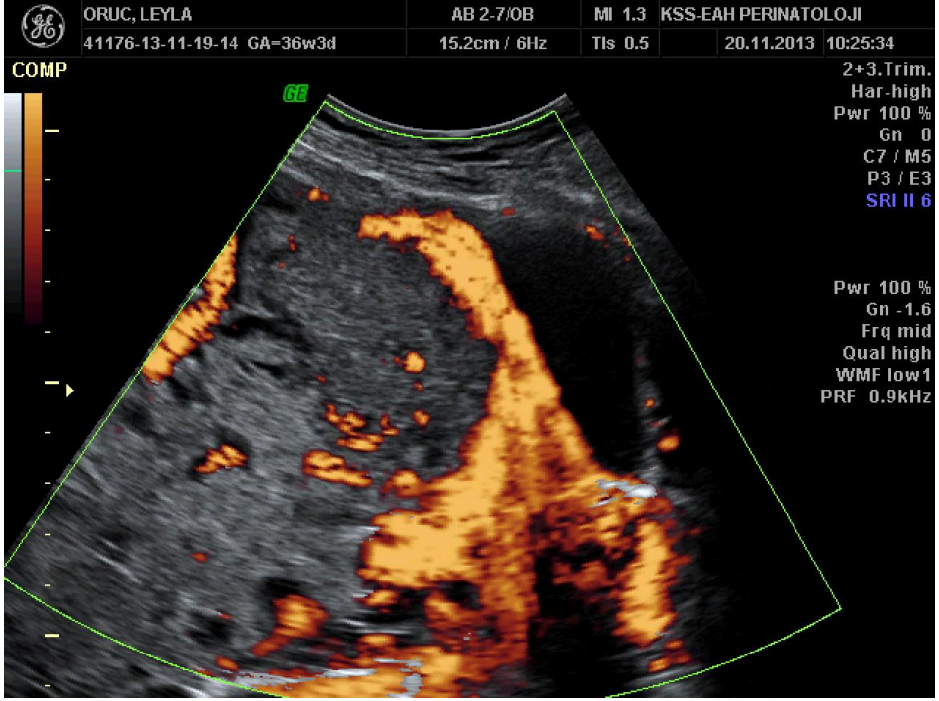
ORUC, LEYLA
AB 2-7/OB
MI 1.3
KSS-EAH PERINATOLOJI
41176-13-11-19-14 GA=36w3d
15.2cm / 6Hz
TIs 0.5
20.11.2013
10:25:34
COMP
2+3.Trim.
Har-high
Pwr 100 %
Gn 0
C7 / M5
P3 / E3
SRI II 6
Pwr 100 %
Gn -1.6
Frq mid
Qual high
WMF low1
PRF 0.9kHz

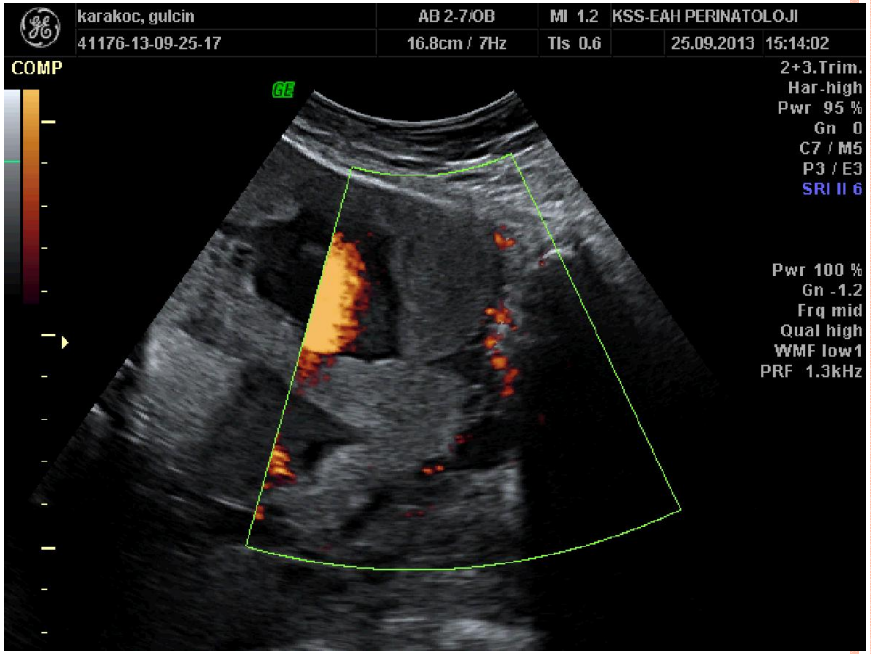
karakoc, gulcin
AB 2-7/OB
MI 1.2
KSS-EAH PERINATOLOJI
41176-13-09-25-17
16.8cm / 7Hz
TIs 0.6
25.09.2013
15:14:02
COMP
2+3.Trim.
Har-high
Pwr 95 %
Gn 0
C7 / M5
P3 / E3
SRI II 6
Pwr 100 %
Gn -1.2
Frq mid
Qual high
WMF low1
PRF 1.3kHz

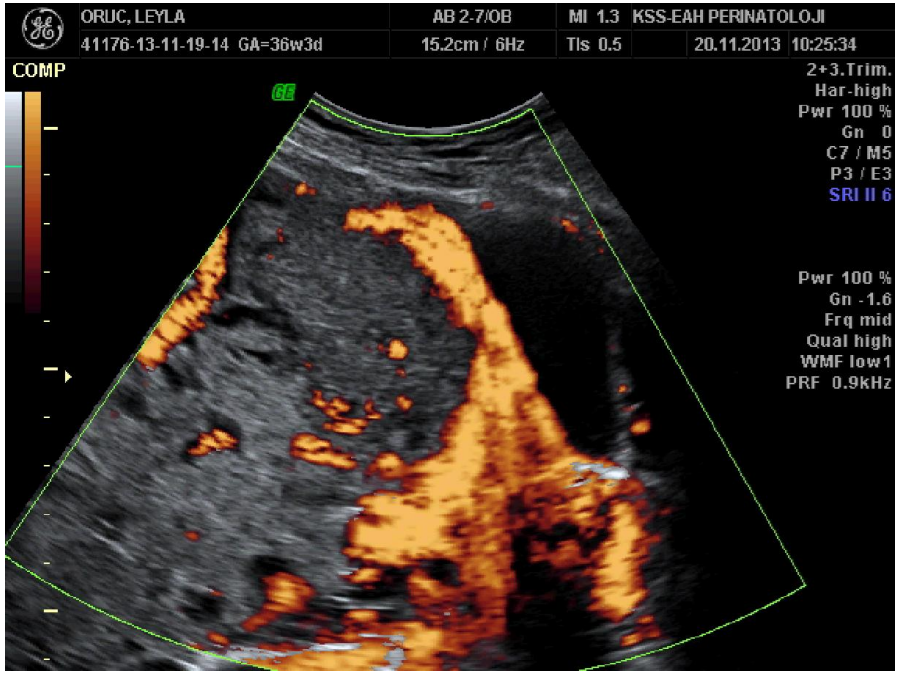
ORUC, LEYLA
AB 2-7/OB
MI 1.3
KSS-EAH PERINATOLOJI
41176-13-11-19-14 GA=36w3d
15.2cm / 6Hz
TIs 0.5
20.11.2013
10:25:34
COMP
2+3.Trim.
Har-high
Pwr 100 %
Gn 0
C7 / M5
P3 / E3
SRI II 6
Pwr 100 %
Gn -1.6
Frq mid
Qual high
WMF low1
PRF 0.9kHz

ucar, latife
RAB 2-5L/OB
MI 1.1
KSS-EAH PERINATOLOJI
41176-13-10-24-1 GA=28w3d
3.5/15.6cm / 6Hz
TIs 0.3
24.10.2013
00:53:00
3D Angio
Qual high1
B56°/V35°
SRI II 3
3D Static PD
(17 / 61)

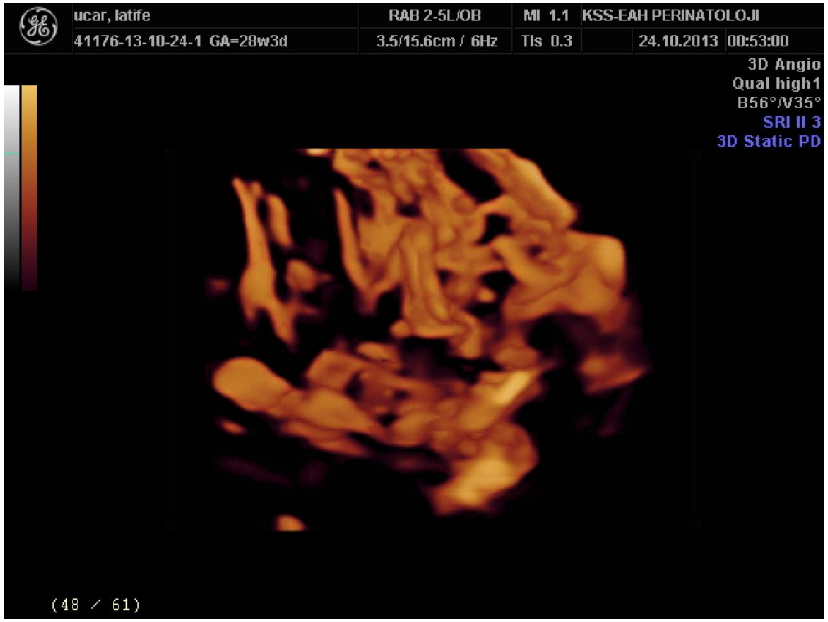
ucar, latife
RAB 2-5L/OB
MI 1.1
KSS-EAH PERINATOLOJI
41176-13-10-24-1 GA=28w3d
3.5/15.6cm / 6Hz
TIs 0.3
24.10.2013
00:53:00
3D Angio
Qual high1
B56°/V35°
SRI II 3
3D Static PD
(48 / 61)

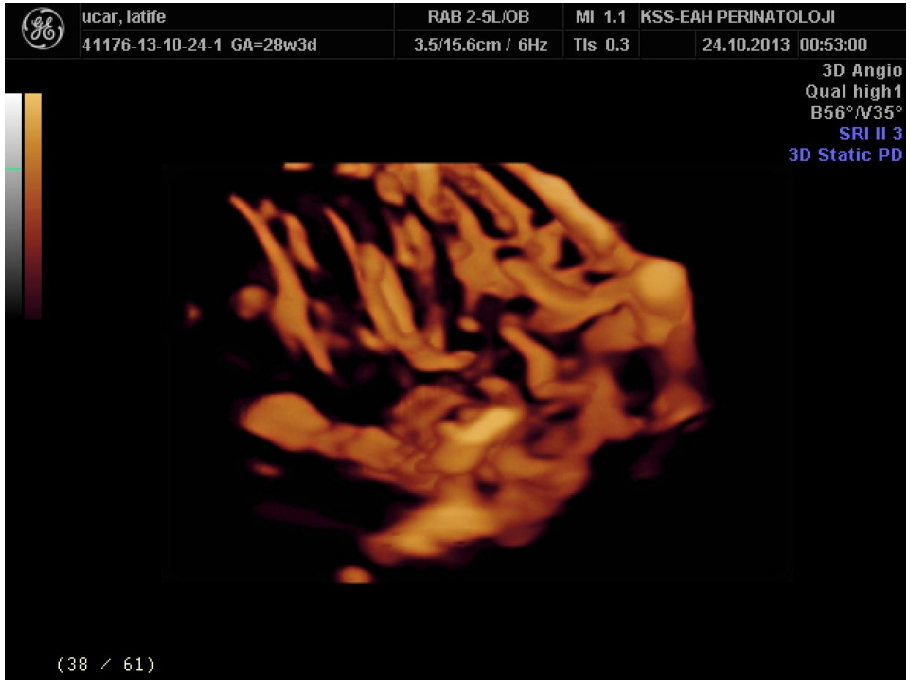
ucar, latife
RAB 2-5L/OB
MI 1.1
KSS-EAH PERINATOLOJI
41176-13-10-24-1 GA=28w3d
3.5/15.6cm / 6Hz
TIs 0.3
24.10.2013
00:53:00
3D Angio
Qual high1
B56°/V35°
SRI II 3
3D Static PD
(38 / 61)

Accepted Manuscript

Accuracy of ultrasound for the prediction of placenta accreta

Zachary S. Bowman, MD, PhD Alexandra G. Eller, MD Anne M. Kennedy, MB BCh, BAO Douglas S. Richards, MD Thomas C. Winter, Paula J. Woodward, MD Robert M. Silver, MD

PII: S0002-9378(14)00239-7

DOI: 10.1016/j.ajog.2014.03.029

Reference: YMOB 9729

To appear in: *American Journal of Obstetrics and Gynecology*

Received Date: 17 December 2013

Revised Date: 30 January 2014

Accepted Date: 10 March 2014

Results: Six investigators examined 229 ultrasound studies from 55 patients with accreta and 56 controls for 1,374 independent observations. 1,205/1,374 (87.7% overall, 90% controls, 84.9% cases) studies were given a diagnosis. There were 371 (27.0%) true positives; 81 (5.9%) false positives; 533 (38.8%) true negatives, 220 (16.0%) false negatives, and 169 (12.3%) with uncertain diagnosis. Sensitivity, specificity, PPV, NPV, and accuracy were 53.5%, 88.0%, 82.1%, 64.8%, and 64.8%, respectively. In multivariate analysis, true positives were more likely to have placental lacunae (OR 1.5, 95%CI 1.4-1.6), loss of retroplacental clear space (OR 2.4, 95%CI 1.1-4.9), or abnormalities on color Doppler (OR 2.1, 95%CI 1.8-2.4).

Conclusion: Ultrasound for the prediction of placenta accreta may not be as sensitive as previously described.

Table 1. Diagnostic performance of different ultrasound modalities

	Sensitivity (%)	Specificity (%)	Positive predictive value (%)	Risk
Greyscale	95	76	82	93
Colour Doppler	92	68	76	89
Three-dimensional power Doppler	100	85	88	100

© Royal College of Obstetricians and Gynaecologists

Prenatal İdentİfİcatİon of İnvasİve placentatİon usİng ultrasound: systematİc revİew and meta-analysİs.

F.D'Antonİo, C. Iacovella and A. Bhİde. Ultrasound Obstet Gynecol 2013; 42: 509–517

- 23 çalışma, 3707 gebe
  - Antenatal invazif plasenta tanısı
    - Sensitivite %90,72
    - Spesifite %96,94
  - En prediktif US bulgusu ise Renkli Doppler
    - Sensitivite %90,74
    - Spesifite %87,68

AOGS
ACTA Obstetricia et Gynecologica Scandinavica

AOGS MAIN RESEARCH ARTICLE

MRI in the diagnosis and surgical management of abnormal placentation

JOSÉ MIGUEL PALACIOS-JARAQUEMADA[1,2], CLAUDIO HERNÁN BRUNO[1] & EDUARDO MARTÍN[1]

[1]South Scientific Foundation, Lomas de Zamora, Buenos Aires, and [2]J.J. Naon Morphological Institute, School of Medicine, University of Buenos Aires, Buenos Aires, Argentina

Acta Obstetricia et Gynecologica Scandinavica © 2012

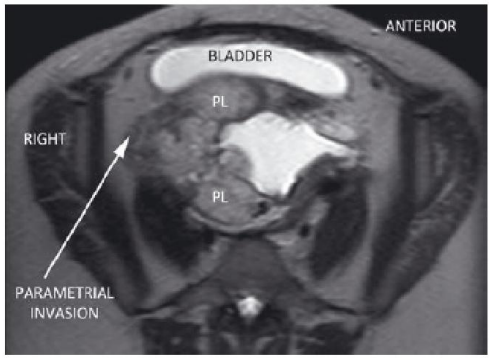

Figure 1. MRI axial slice that shows a right parametrial placental invasion with an absence of lateral myometrium (white arrow). Notice that the plane between bladder and the uterus is almost normal. Clinical background revealed two previous abortions separated by five months. PL, placenta.

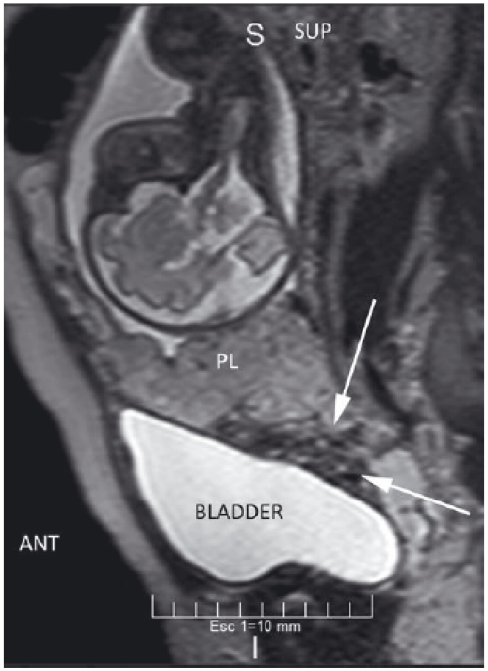

Figure 2. Anterior placenta percreta: MRI sagittal slice shows an special and uncommon vascular hyperplasia between the uterine cervix and the trigon (white arrows). Cervico-trigonal vascular hyperplasia (CTVH) represents a particular growing of colpouterine collateral blood supply in lower abnormal placentations. PL, placenta.

Placental MRI provides excellent characterization of the degree and extension of placental invasion. Its usefulness in cases of adherent placentation is directly associated to the therapeutic measures, especially where dissection maneuvers are needed. Diagnostic differences between ultrasound and MRI related to the presence or not of placenta previa and uterine scar thinning.

Key Message

An accurate preoperatory diagnosis is one of the best methods to anticipate complications in abnormal placentation. However, the precise diagnostic are related with technical details, study preparation and the specific training of radiologist. As happened before with the ultrasound, advances in the MR diagnosis are depending of continuous feedback.

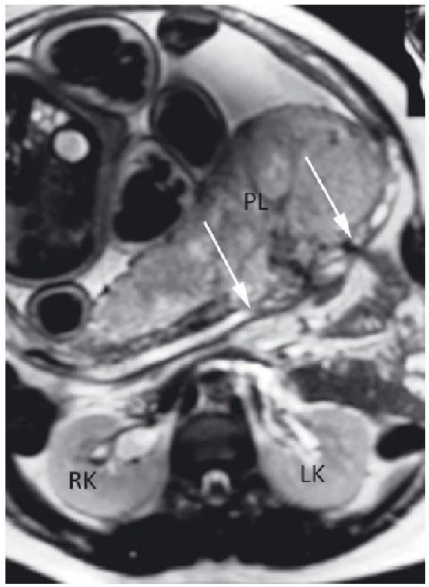

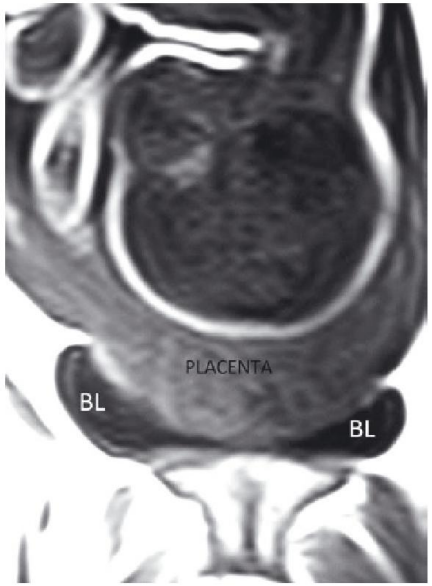

Prenatal Identification Of Invasive Placentation Using Magnetic Resonance Imaging (MRI): A Systematic Review And Meta-analysis.

- 18 çalışma, 1010 hasta..... meta-analiz
- MRI ve USG aynı doğruluk öngörüsüne sahip

Ultrasound Obstet Gynecol. 2014 Feb

OPEN ACCESS Freely available online PLOS | ONE

Accuracy of Ultrasonography and Magnetic Resonance Imaging in the Diagnosis of Placenta Accreta

Anne-Sophie Riteau[1,2], Mikael Tassin[1], Guillemette Chambon[1], Claudine Le Vaillant[2], Jocelyne de Laveaucoupet[3], Marie-Pierre Quéré[4], Madeleine Joubert[5], Sophie Prevot[6], Henri-Jean Philippe[2], Alexandra Benachi[1]*

April 14, 2014

PA tanısında USG esastır, MR USG'yi tamamlar

Abstract

Purpose: To evaluate the accuracy of ultrasonography and magnetic resonance imaging (MRI) in the diagnosis of placenta accreta and to define the most relevant specific ultrasound and MRI features that may predict placental invasion.

Material and Methods: This study was approved by the institutional review board of the French College of Obstetricians and Gynecologists. We retrospectively reviewed the medical records of all patients referred for suspected placenta accreta to two university hospitals from 01/2001 to 05/2012. Our study population included 42 pregnant women who had been investigated by both ultrasonography and MRI. Ultrasound images and MRI were blindly reassessed for each case by 2 raters in order to score features that predict abnormal placental invasion.

Results: Sensitivity in the diagnosis of placenta accreta was 100% with ultrasound and 76.9% for MRI (P = 0.03). Specificity was 37.5% with ultrasonography and 50% for MRI (P = 0.6). The features of greatest sensitivity on ultrasonography were intraplacental lacunae and loss of the normal retroplacental clear space. Increased vascularization in the uterine serosa-bladder wall interface and vascularization perpendicular to the uterine wall had the best positive predictive value (92%). At MRI, uterine bulging had the best positive predictive value (85%) and its combination with the presence of dark intraplacental bands on T2-weighted images improved the predictive value to 90%.

Conclusion: Ultrasound imaging is the mainstay of screening for placenta accreta. MRI appears to be complementary to ultrasonography, especially when there are few ultrasound signs.

TANI - **MRI**

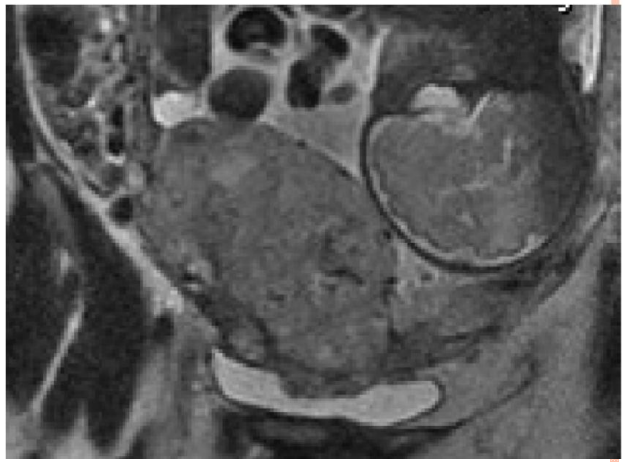

BULGULAR

- Mesane içine doğru **uterin kabartı**
- Plasenta içinde **hetorejen sinyal yoğunluğu**
- T2 ağırlıklı görüntüde **intraplasental koyu bandlar**
- **Anormal plasental vaskularite**

•PL önde ise, İNVAZYON DERİNLİĞİ VE KOMŞU ORGAN İNVAZYONLARINI SAPTAMADA daha faydalı

•USG İLE ZOR GÖRÜNTÜLENEN OLGULAR: Arka plasenta akreta olasılığı, yüksek BMI...

•TANIDA ZORLANILAN OLGULARDA KULLANILMALI

PRENATAL TANI- SONUÇ

- USG bulguları ile tanı konulur (18-24 HAFTA)
- Hiçbir tanı metodu %100 doğruluğu sağlamaz
- 1=< C/S sonrası PP veya aşağı yerleşimli PL olan hastalarda US bulguları varlığında tanı çok olasıdır
- Normal plasenta US bulguları, tanıyı oldukça ekarte ettirir
- Renkli Doppler tanıyı desteklemeye yardımcıdır
- MRI ; US bulguları yetersiz olduğunda faydalı olabilir

TANI - DİĞER

- Sistoskopi, sigmoidoskopi
- TİT....Hematüri

- AFP
- Free beta HCG
- Kreatin kinaz

- **Histoloji: Villuslar myometrium içinde saptanır, arada desidua yoktur**

- **Fokal akreta**……..histerektomi yapılmadığında **TANI GÖZLEMLE (**myometriuma yapışık plasenta parçaları, küretaj) **konulur**

AOGS
ACTA Obstetricia et Gynecologica Scandinavica

AOGS MAIN RESEARCH ARTICLE

Prenatal diagnosis of abnormally invasive placenta reduces maternal peripartum hemorrhage and morbidity

FRÉDÉRIC CHANTRAINE[1,2], THORSTEN BRAUN[3,4], MARKUS GONSER[5], WOLFGANG HENRICH[3] & BORIS TUTSCHEK[6,7]

[1]Department of Obstetrics and Gynecology, CHR Citadelle, Liège, Belgium, [2]Laboratory of Tumor and Development Biology, CHU, GIGA-Cancer, University of Liège, Liège, Belgium, [3]Charité Campus Virchow, Department of Obstetrics, University Hospital Berlin, Berlin, Germany, [4]Division of Perinatal Programming, Charité Campus Virchow, Berlin, Germany, [5]Horst Schmidt Kliniken, Wiesbaden, Germany, [6]Center for Fetal Medicine and Gynecological Ultrasound, Basel, Switzerland, and [7]Heinrich Heine University, Düsseldorf, Germany

Objective. Abnormally invasive placenta (AIP) poses diagnostic and therapeutic challenges. We analyzed clinical cases with confirmed placenta increta or percreta. *Design.* Retrospective case series. *Setting.* Multicenter study. *Population.* Pregnant women with AIP. *Methods.* Chart review. *Main outcome measures.* Prenatal detection rates, treatment choices, morbidity, mortality and short-term outcome. *Results.* Sixty-six cases were analyzed. All women and all but three fetuses survived; 57/64 women (89%) had previous uterine surgery. In 26 women (39%) the diagnosis was not known before delivery (Group 1), in the remaining 40 (61%) diagnosis had been made between 14 and 37 weeks of gestation (Group 2). Placenta previa was present in 36 women (54%). In

Key Message

Unknown abnormally invasive placenta led to significantly more emergency hysterectomies and mass transfusions during or immediately after delivery. Prenatal diagnosis of abnormally invasive placenta reduces morbidity.

YÖNETİM
PL AKRETA ŞÜPHESİNDE DOĞUM

- **Prenatal tanı, sonuçları düzeltiyor ve transfüzyon gereksinimini azaltıyor**

TANI KONULAN veya TANISI ŞÜPHELİ HASTA,

- **Uygun cerrahi aletlerin**
- **Kan bankasının**
- **YBÜ'lerinin olduğu hastaneye,**

VAKİT KAYBETMEDEN YÖNLENDİRİLMELİDİR

YÖNETİM

- Danışmanlık-bilgi verme önemlidir:

  HASTA-EŞİ, tanı ve potansiyel sonuçları hakkında **ayrıntılı bilgilendirilmeli, onayları alınmalı**

- Hasta fertilitesinin korunmasını isterse **konservatif tedaviler** ve **olası riskleri anlatılmalıdır**

- **Optimum doğum zamanı** belirlenmeli ve gerekli hazırlıklar yapılmalı

- Antepartum kanama yada komplikasyon yoksa:

  Planlanmış geç preterm doğum yaptırılması, **plansız termde acil doğum riskini azaltmak** için kabul edilebilir

ACOG 2012

- PI invazyon anomalisi şüphesi kuvvetli hastalar, yeterli şartları sağlayan **tersiyer merkezlere transfer edilmelidir**
- Stabil hastada, **34. haftada, AS yapılmadan C/S** planlanmalıdır (**RCOG; 36-37**)
- Celestone yapılması kişisel olmalı
- **Deneyimli cerrahi ekip ve ürolog, jin onkolog, genel cerrahi uzmanı** hasta güvenliği açısından önemlidir
- PL Akreta şüpheli olguda **gnl önerilen PL'nın yerinde bırakılarak sezaryen histerektomi yapılmasıdır**
- Bununla birlikte cerrahi td kişiselleştirilebilir.

YÖNETİM - ANTENATAL DÖNEM

- Varsa, anemi düzeltilmeli
- Preterm doğum riski varsa; tokoliz ve steroid
- Rh (-) olguda vajinal kanama varlığında Anti-D Ig
- NST ve/veya BPP yeri yok
- Seri sonografik değerlendirme yararlı değil

PREOP HAZIRLIK

- Plasenta yerleşimi **haritalandırılır, cilt ve uterus insizyonları belirlenir**
- **Kan** ve **kan ürünleri** hazırlanır (1:1:1)
- **Anestezi konsültasyon**
- En az 2 adet **damar yolu açılır**, gerekirse CVP kateter
- 3 yollu **Foley kateter**
- **Antibiyotik** profilaksisi
- **YBÜ'de yatak ayrılır**
- Gerek görüldüğünde **jinekolojik onkoloji, üroloji, genel cerrahi ve damar cerrahisi** ile görüşülür ve
- Olası intraoperatif komplikasyonlar tartışılır
- Periopertif üreterik stent (?)
- Pelvik arter oklüzyonu (?) hazırlığı
- Common iliak arter oklüzyonu (?) hazırlığı

PPT PREOP KONTROL LİSTESİ

TARİH ve BARKOD:

AD SOYAD:

ESKİ DOĞUMLARIN ANAMNEZİ: KAÇ ESKİ C/S VAR?

G1: NSD C/S

G2: NSD C/S

G3: NSD C/S

G4: NSD C/S

GEÇİRİLMİŞ DİĞER UTERUS AMELİYATLARI (MYOMEKTOMİ GİBİ):

SAT ve G. HAFTASI:

İLK TRİMESTER USG'YE GÖRE G. HAFTA:

İLK TRİMESTER USG GÖRÜNTÜSÜ VAR MI? SKAR GEBELİĞİ Mİ?

USG BULGULARI KONTROL LİSTESİ:

- **Plasenta lokalizasyonu (ayrıntılı tanımla):**
- **Plasenta arkası hipoekoik zonun kaybı var mı?**
- **Plasentada multipl vaskuler lakün var mı? Sayısı?**
- **Utero-plasental sınırında, myometrium-mesane arayüzünde veya uterus serozası kesitinde kan damarları veya plasental doku köprüsü var mı?**
- **Plasenta arkasındaki myometrium doku kalınlığı kaç mm?**
- **3 boyutlu Power Doppler ile çok sayıda damar görüntüleniyor mu?**

KAN GRUBU, Hb, Htc, Plt:

Kan transfüzyonu yapılmış mı? Kaç Ü ve ne zaman?

Fe kullanıyor mu?

Celestone yapıldı mı?

PLANLANAN C/S TARİH ve GH:

EŞİ ve KENDİSNİN İMZALARI TAMAM MI?

PREOP RUTİN TETKİKLER TAMAM MI?

ANESTEZİ KONSÜLTASYONU TAMAM MI?

KAN HAZIRLIĞI TAMAM MI (4 Ü KROSLU, 4 Ü KROSSUZ):

TABLE 3

The following tool may be helpful if consolidated in the patient record for easy access and quick reference should an emergency occur[a]

Patient name	
Medical record no.	
Estimated due date	
Preoperative diagnosis of accreta; specify:	accreta/increta/percreta
Placenta location	
Relevant ultrasound findings	
Relevant MRI findings	
Obstetric history	
No. of prior cesarean deliveries	
Other prior uterine surgery	
Blood type	
Antibody screen	
Date and value of most recent hematocrit/hemoglobin	
Date and value of most recent creatinine	
Iron supplementation; if yes, specify type, dose	yes/no
Epogen in this pregnancy; if yes, give dates	yes/no
Transfusion in this pregnancy; if yes, give dates	yes/no
Date of planned surgery	
Planned surgery location and contact no.	
Gestational age at planned delivery	
Antenatal glucocorticoids; if yes, give dates	yes/no
Primary obstetrician; list name and contact no.	
Preoperative consultations and notifications[a]	If yes, list name and contact no.
Obstetric anesthesiologist/anesthesiologist	no/yes _____
Maternal fetal medicine specialist	no/yes _____
Neonatologist/pediatrician	no/yes _____
Gynecologic oncologist/pelvic surgeon	no/yes _____
Urologist	no/yes _____
General surgeon	no/yes _____
Vascular surgeon	no/yes _____
Interventional radiologist	no/yes _____
Blood bank specialist/hematologist	no/yes _____
Cell-saver specialist	no/yes _____
Laboratory specialist	no/yes _____
Intensive care specialist	no/yes _____

MRI, magnetic resonance imaging.

[a] Individual practices and circumstances will vary. This example does not indicate that certain evaluations or consultations are anticipated or expected in all cases.

SMFM. Placenta accreta. Am J Obstet Gynecol 2010.

Cerrahi seçenekler

1. Sezaryen histerektomi
2. Konservatif tedavi
   - **Plasentanın yerinde bırakılması**
   - **Plasenta ile birlikte invaze myometrium çıkarılması**
   - **Plasentanın çıkarılıp, sütur ve balon tamponad ile kanama kontrolü**

- İyi seçilmiş olgularda konservatif kalınabilir (Garmi, G 2012)

Cerrahi tedavide uygulanacak tedavi yöntemi her hastaya göre kişiselleştirilmeli

(Committee on Obstetric practice 2012)

CERRAHİ

- **Dorsal litotomi pozisyonu**
- **Göbek altı-üstü median/paramedian insizyon, Pfannenstiel ?**
- **Uterus insizyonu (Fundal vertikal-transvers)**
- **Plasenta elle çıkartılmaya çalışılmaz**
- **Plasenta ayrılmazsa kordon bağlanır, uterus kapatılarak histerektomiye başlanır.**

HİSTEREKTOMİ

- Plasentayı örten uterus serozasının delinmesinden kaçınmalı
- Mesane tutulumunda sistotomiye gerek duyulabilir
- Mesanenin etkilenen kısmı çıkarılabilir (uterusa çıkarılamayacak kadar yapışık ise)
- Bazı hastalarda **subtotal histerektominin** başarılı
- Alt uterin segment/servikal plasental implantasyondan kaynaklı persistan kanamalarda total histerektomi gerekir

DOI: 10.1111/1471-0528.12405
www.bjog.org

The management and outcomes of placenta accreta, increta, and percreta in the UK: a population-based descriptive study

KE Fitzpatrick,[a] S Sellers,[b] P Spark,[a] JJ Kurinczuk,[a] P Brocklehurst,[c] M Knight[a]

[a] National Perinatal Epidemiology Unit, University of Oxford, Oxford, UK [b] University Hospitals Bristol NHS Trust, Bristol, UK [c] Institute for Women's Health, University College London, London, UK
Correspondence: KE Fitzpatrick, National Perinatal Epidemiology Unit, University of Oxford, Old Road Campus, Oxford OX3 7LF, UK. Email kate.fitzpatrick@npeu.ox.ac.uk

Accepted 22 May 2013. Published Online 7 August 2013.

Plasentaya dokunmadan histerektomi yapma veya yerinde bırakmada: **DAHA AZ KANAMA-DAHA AZ TRANSFÜZYON GEREĞİ**

Objective To describe the management and outcomes of placenta accreta, increta, and percreta in the UK.

Design A population-based descriptive study using the UK Obstetric Surveillance System (UKOSS).

Setting All 221 UK hospitals with obstetrician-led maternity units.

Population All women diagnosed with placenta accreta, increta, and percreta in the UK between May 2010 and April 2011.

Methods Prospective case identification through the monthly mailing of UKOSS.

Main outcome measures Median estimated blood loss, transfusion requirements.

Results A cohort of 134 women were identified with placenta accreta, increta, or percreta: 50% (66/133) were suspected to have this condition antenatally. In women with a final diagnosis of placenta increta or percreta, antenatal diagnosis was associated with reduced levels of haemorrhage (median estimated blood loss 2750 versus 6100 ml, $P = 0.008$) and a reduced need for blood transfusion (59 versus 94%, $P = 0.014$), possibly because antenatally diagnosed women were more likely to have preventative therapies for haemorrhage (74 versus 52%, $P = 0.007$), and were less likely to have an attempt made to remove their placenta (59 versus 93%, $P < 0.001$). Making no attempt to remove any of the placenta, in an attempt to conserve the uterus or prior to hysterectomy, was associated with reduced levels of haemorrhage (median estimated blood loss 1750 versus 3700 ml, $P = 0.001$) and a reduced need for blood transfusion (57 versus 86%, $P < 0.001$).

Conclusions Women with placenta accreta, increta, or percreta who have no attempt to remove any of their placenta, with the aim of conserving their uterus, or prior to hysterectomy, have reduced levels of haemorrhage and a reduced need for blood transfusion, supporting the recommendation of this practice.

Keywords Abnormal placental adherence, haemorrhage, placenta accreta/increta/percreta.

AOGS
ACTA Obstetricia et Gynecologica Scandinavica

AOGS COMMENTARY

Important surgical measures and techniques at cesarean hysterectomy for placenta previa accreta

SHIGEKI MATSUBARA[1,*], TOMOYUKI KUWATA[1], RIE USUI[1], TAKASHI WATANABE[1], AKIO IZUMI[1], AKIHIDE OHKUCHI[1], MITSUAKI SUZUKI[1] & MANABU NAKATA[2]

[1]Departments of Obstetrics and Gynecology, and [2]Radiology, Jichi Medical University, Shimotsuke, Japan

Acta Obstetricia et Gynecologica Scandinavica © 2013

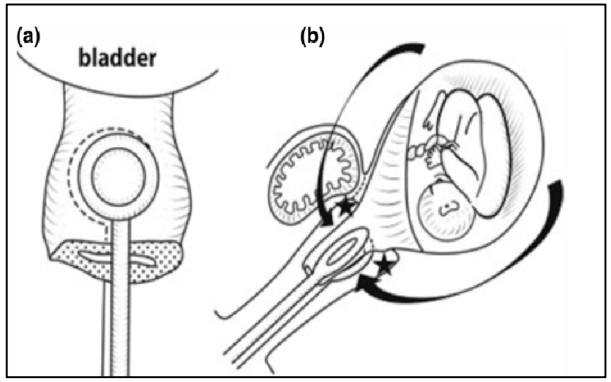

- 8 önlem
  - Intra-arterial balon katater yerleştirilmesi
  - Üreteral stent
  - Serviksi tutma tekniği
  - Uterin fundal transvers insizyon
  - Uterotoniklerden kaçınma
  - Overyan ligamentin ‘M cross double’ ligasyonu
  - Mesaneye doldurma (300 mL)
  - Parametrium ve paraserviksin kesilmesi; uterin taraf klamplenir veya distal kenar çift taraflı bağlanır

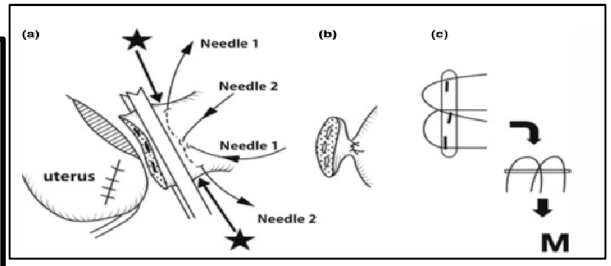

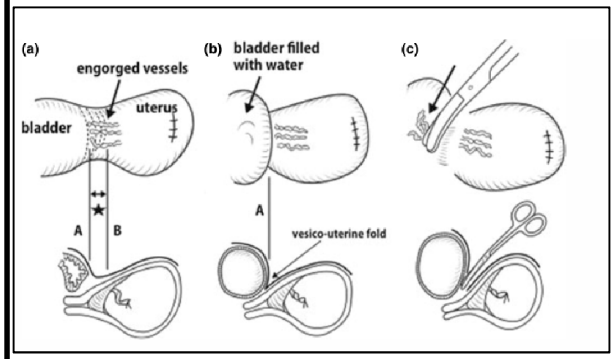

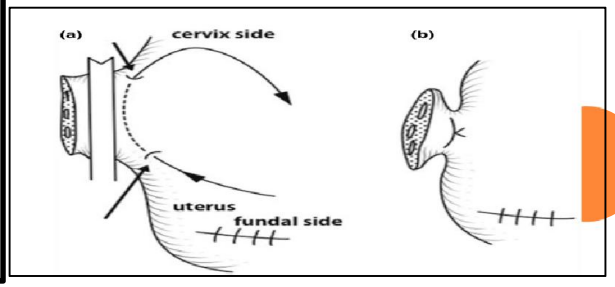

HİSTEREKTOMİ TEKNİĞİMİZ

- Praflaktik hipogastrik arter bağlamıyoruz, embolizasyon yapmıyoruz, balon yerleştirmiyoruz
- Üreter stenti kullanmıyoruz
- Serviksi tutmuyoruz

- Mesane 200-250 cc dolduruyoruz
- Plasentanın alt ucundan uterusu çıkarıyoruz
- Dren mutlaka

- Uygun olgularda **parsiyel rezeksiyon** yapıyoruz
- Konservatif olgularda, myometrial süturlar ve bakri balon tamponadı yapıyoruz
- Plasentayı yerinde bırakma deneyimimiz yok

PERİPARTUM HİSTEREKTOMİNİN KOMPLİKASYONLARI

- Perioperatif mortalite (%1-6)
- Masif kan kaybı (ort. 5 L): DIK, Sheehan S, pulmoner ödem, ARDS
- Mesane yaralanması (%6-29)
- Üreter yaralanması (%7)
- Febril komplikasyonlar
- Barsak disfonksiyonu
- Re-operasyon
- Rekürren kanamada re-eksplorasyon için eşik değer düşük tutulmalı

PLASENTAYI YERİNDE BIRAKMA

- Fertilite devamı isteği
- Uterusun alınmasının mümkün olmadığı durumlar
- Çevre dokulara aşırı invazyondan dolayı uterusun çıkarılmasının tehlikeli olduğu durumlar

- Kanama sonucu **gecikmiş histerektomi riski** vardır

- **Metotreksat** tedavisi ve **selektif embolizasyon** eklenebilir
- Bu tedavilerin güvenliği ve etkinliği bilinmemektedir.
- **Septik şok, ciddi kanama ve tromboembolizm** gibi ciddi komplikasyonlar vardır

AOGS
ACTA Obstetricia et Gynecologica Scandinavica

AOGS SHORT RESEARCH REPORT

Conservative management of abnormally invasive placenta: four case reports

ANGELA RAMONI*, EVA-MARIA STROBL, JOHANNA TIECHL, MAGDALENA RITTER & CHRISTIAN MARTH

Department of Obstetrics and Gynecology, Innsbruck Medical University, Innsbruck, Austria

Acta Obstetricia et Gynecologica Scandinavica © 2013

Abstract

Prenatal diagnosis of placenta increta and percreta is essential to avoid potentially life-threatening hemorrhage by optimizing peripartal management. Invasive placentation presents significant challenges at cesarean section even for highly skilled surgeons. In the four cases of placenta increta/percreta presented here we tried to avoid hysterectomy by leaving the placenta behind and tried to accelerate regression of placental tissue by administering methotrexate. The outcome in each of the four women was different, but no major bleeding occurred in any of the cases. Close follow-up for many weeks is mandatory.

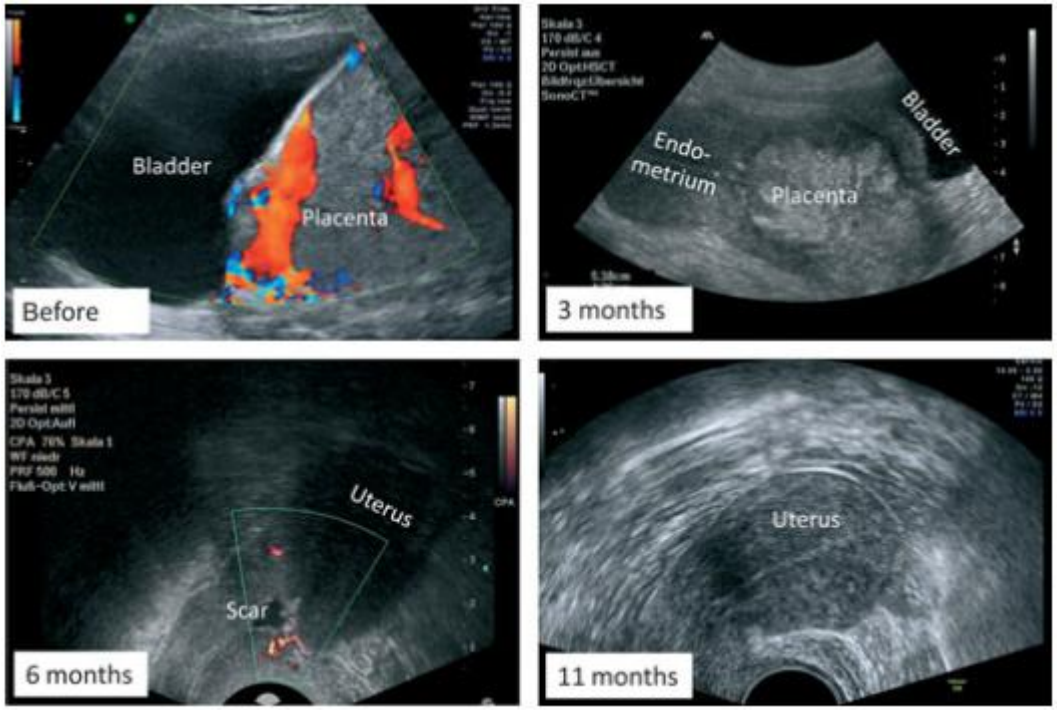

Table 1. Outcome of four patients with placenta percreta.

Patient	Previous cesarean section	Diagnosis	Clinical course	Units of packed red blood cells
24y G4/P2	2	Placenta previa totalis percreta infiltration of the bladder	Febrile infection day 62 successfully treated with antibiotics; placenta vanished after 6 months	0
29y G7/P3	1	Placenta previa totalis percreta infiltration of the bladder	Febrile infection with bleeding day 58; vaginal removal of placenta and insertion of Bakri-balloon for 12 h	2 on day 59
34y G9/P6	3	Placenta previa totalis percreta infiltration of the bladder	Bleeding on day 18 necessitating hysterectomy; no bladder lesions	4 on day 18
29y G2/P2	1	Placenta previa totalis percreta infiltration of the bladder	Vaginal removal of placenta on day 59, bleeding necessitating hysterectomy no bladder lesions	6 on day 59

MTX 1mg&kg haftada bir

Close follow-up for many weeks is mandatory.

Takip: AB, vaginal kültür, CRP, β-hcg, hemogram, usg haftada 1

OBSTETRICS & GYNECOLOGY VOL. 115, NO. 3, MARCH 2010

Maternal Outcome After Conservative Treatment of Placenta Accreta

Loïc Sentilhes, MD, Clémence Ambroselli, MD, Gilles Kayem, MD, PhD, Magali Provansal, MD, Hervé Fernandez, MD, PhD, Franck Perrotin, MD, PhD, Norbert Winer, MD, PhD, Fabrice Pierre, MD, PhD, Alexandra Benachi, MD, PhD, Michel Dreyfus, MD, PhD, Estelle Bauville, MD, Dominique Mahieu-Caputo, MD, PhD, Loïc Marpeau, MD, PhD, Philippe Descamps, MD, PhD, François Goffinet, MD, PhD, and Florence Bretelle, MD, PhD

Table 3. Peripartum Management and Modalities of Conservative Treatment for Patients With Placenta Accreta, Including Placenta Percreta

Characteristic	Placenta Accreta, Including Percreta (n=167)
Hysterotomy (n=139)	
Fundal	71 (51.1)
Low transverse	68 (48.9)
Placenta left in situ	167 (100)
Partially	99 (59.3)
Entirely	68 (40.7)
Preoperative ureteric stent placement	6 (3.6)
Uterotonic administration	167 (100)
Primary postpartum hemorrhage	86 (51.5)
No additional uterine devascularization procedure	
Additional uterine devascularization procedure	
Pelvic arterial embolization*	
Vessel ligation*	45 (26.9)
Stepwise uterine devascularization	15 (9.0)
Hypogastric artery ligation	23 (13.8)
Stepwise uterine devascularization and hypogastric artery ligation	7 (4.2)
Uterine compression suture*	16 (9.6)
Balloon catheter occlusion	0
Methotrexate administration	21 (12.6)

Table 4. Maternal Morbidity After Conservative Treatment for Placenta Accreta, Including Placenta Percreta

Characteristic	Placenta Accreta, Including Percreta (n=167)
Primary hysterectomy	18 (10.8)
Cause of primary hysterectomy	
Primary postpartum hemorrhage	18/18 (100)
Postpartum prophylactic antibiotic therapy more than 5 d	54 (32.3)
Transfusion patients	70 (41.9)
Units of packed RBCs transfused more than 5	25 (15.0)
Transfer to intensive care unit	43 (25.7)
Duration of stay in intensive care unit (d)	2.36±1.93
Acute pulmonary edema	1 (0.6)
Acute renal failure	1 (0.6)
Adjacent organ injury	1 (0.6)
Septic shock	1 (0.6)
Sepsis*	7 (4.2)
Infection	47 (28.1)
Endometritis	15 (9.0)
Wound infection	8 (4.7)
Peritonitis	2 (1.2)
Pyelonephritis	2 (1.2)
Vesicouterine fistula	1 (0.6)
Uterine necrosis	2 (1.2)
Isolated postpartum fever higher than 38.5°C for 24 h	17 (10.2)
Deep vein thrombophlebitis or	3 (1.8)
	18 (10.8)
	2/18 (11.1)
	2/18 (11.1)
	2/18 (11.1)
	4/18 (22.2)
	8/18 (44.5)
	18 (10.8)
Median interval from delivery to delayed hysterectomy (d)	22 (9–45)
Cause of delayed hysterectomy	
Secondary postpartum hemorrhage	8/18 (44.4)
Sepsis	2/18 (11.1)
Secondary postpartum hemorrhage and sepsis	3/18 (16.7)
Vesicouterine fistula	1/18 (5.6)
Uterine necrosis and sepsis†	2/18 (11.1)
Arteriovenous malformation	1/18 (5.6)
Maternal request	1/18 (5.6)
Death	1 (0.6)
Success of conservative treatment	131 (78.4)

Başarı %78,4 (36/167 histerektomi)
Ciddi morbidite %6
Mortalite %0,6 (1 olgu, MTX yan etkisi)

AOGS
ACTA Obstetricia et Gynecologica Scandinavica

AOGS REVIEW ARTICLE

Management of placenta percreta: a review of published cases

CAROLINE CLAUSEN[1,*], LARS LÖNN[1,2] & JENS LANGHOFF-ROOS[3]

[1]Department of Cardiovascular Radiology, [2]Department of Vascular Surgery, and [3]Department of Obstetrics and Gynecology, Rigshospitalet, Copenhagen University Hospital, Copenhagen, Denmark

Acta Obstetricia et Gynecologica Scandinavica **93** (2014) 138–143

tions. A PubMed search was performed in April 2013 and the final review included 119 published placenta percreta cases. Conservative management, where the placenta is left in situ for resorption, seems to be associated with severe long-term complications of hemorrhage and infections, including a 58% risk that a hysterectomy will eventually be needed up till nine months after the delivery. Local resection seems to be associated with fewer complications within 24 h postoperatively compared with hysterectomy or leaving the placenta in situ. A selection bias in the direction of less severe cases for the local resection technique might in part explain the lower complication rates with that approach. Future prospective data collection activities should include intended as well as actual management, and long-term follow-up of all cases is of vital importance.

Table 1. Surgical procedures and complications in 119 placenta percreta cases

Initial surgical procedure	Hysterectomy	Local resection	Placenta left in situ	*Sum*
No. of cases	66 (56%)	17 (14%)	36 (30%)	119
Mode of cesarean section				
Elective	41 (62%)	16 (94%)	20 (56%)	77 (65%)
Emergency	8 (12%)	1 (6%)	15 (42%)	24 (20%)
Unspecific	17	0	1	18
Complications				
Bladder injury/resection	11	0	6	17
Salpingo-oophorectomy	1	0	1	2
Post-operative hemorrhage	5	2	16	23
Post-operative infection	1	0	9	10
Fistula	2	0	1	
Pulmonary embolism/cardiopulmonary arrest	1	0	3	
Femoral pseudoaneurysm or distal thrombus	4	2	0	
Other re-operation	1	1	3	
Sum	26	5	39	
Secondary hysterectomy				
Emergency	–	0	18	
Planned	–	0	3	3
Cases with one or more complications 0–24 h	19 (30%)	2 (12%)	9 (25%)	30
Cases with one or more complications >24 h	8 (12%)	2 (12%)	22 (61%)	32

Key Message

Conservative management in the sense that the placenta is left in situ for resorption seems to be associated with severe long-term complications of hemorrhage and infections, including a 58% risk of hysterectomy up till nine months after delivery.

21/30= **%58**
HİSTEREKTOMİ

AOGS
ACTA Obstetricia et Gynecologica Scandinavica

AOGS MAIN RESEARCH ARTICLE

Surgical management of placenta accreta: a 10-year experience

SE GRACE TAN[1], THOMAS W JOBLING[2], EUAN M WALLACE[1,3], L JANE MCNEILAGE[2], THOMAS MANOLITSAS[2] & RYAN J HODGES[1,3]

[1]Maternal Fetal Medicine Unit, [2]Department of Gynaecological Oncology, Monash Medical Centre, Southern Health, Victoria, and [3]Department of Obstetrics and Gynaecology, The Ritchie Centre, Monash Institute of Medical Research, Southern Clinical School Monash University, Clayton, Victoria, Australia

Acta Obstetricia et Gynecologica Scandinavica © 2013

Primer cerrahi girişim histerektomidir

Konservatif yönetim için, büyük prospektif çalışmalar yapılana kadar bu tedavi esas olmalıdır

Key Message

A primary surgical approach to management of placenta accreta by hysterectomy is associated with significant maternal morbidity, even when managed in a dedicated quaternary perinatal referral centre. However, this approach should remain the mainstay of care until larger prospective studies of conservative management strategies are reported.

PROFLAKTİK ARTER OKLÜZYONLARI

- **İİA** balon uygulaması kanamayı artırıyor (17 hasta), CİA balon uygulamalı (Clausen C, 2013)
- **İİA** balon yerleştirme sırasında arter rüptürü, APGAR 3-7 doğuyor (Cagnon J 2013)
- Pelvik arter oklüzyonu.....uterus nekrozu (Poujade 2013)
- **IABO y**apılanlarda(15), yapılmayanlara(18) (plasenta elle alınıyor) göre daha az histerektomi, kan kaybı ve tr gereksinimi (Panici PB 2012)
- **Geçici IABO** ile histerektomide kan kaybı az ve op kolay (Andoh S, 2011)
- Geçici **infrarenal aort klempi** de histerektomide kan kaybını azaltır (Chou MM, 2010)
- **UA balon:** Kanama-kan gereksinimi az, fetal risk artar (Sadashivaiah J 2011)

AOGS
ACTA Obstetricia et Gynecologica Scandinavica

AOGS MAIN RESEARCH ARTICLE

Balloon occlusion of the internal iliac arteries in the multidisciplinary management of placenta percreta

CAROLINE CLAUSEN[1], JAKOB STENSBALLE[2,3], CHARLOTTE K. ALBRECHTSEN[4], MARC A. HANSEN[1], LARS LÖNN[1,5] & JENS LANGHOFF-ROOS[6]

Table 1. Summary of demographic characteristics, intraoperative data and outcomes.

Case no.	Age (years)	Gravida/ para	Previous cesarean section/ or previous uterus surgery	Gestational age at delivery (weeks+days)	Balloon occlusion of the internal iliac arteries	Surgical procedure	Intraoperative blood loss (mL)	Packed red blood cell transfusion 0 –24 hour (mL)	Fresh frozen plasma transfusion 0 –24 hour (mL)	Platelet transfusion 0 –24 hour (mL)	Length of surgery (min)
1	33	5/3	3/0	32^{+6}	Yes	Hysterectomy	2000	0	0	0	155
2	32	0/0	0/1[a]	33^{+6}	Yes	Local resection	1900	900	0	0	45
3	34	3/3	2/0	32^{+2}	Yes	Hysterectomy	7000	3900	3300	1500	120
4	34	3/3	2/0	34^{+1}	Yes	Hysterectomy	2000	600	0	0	75
5	36	3/4	2/0	32^{+0}	Yes	Hysterectomy	8450	4200	3600	1500	188
6	34	3/2[a]	1/0	32^{+4}	Yes	Local resection	3500	1800	900	600	80
7	35	1/2	1/0	34^{+3}	Yes	Local resection	1400	0	0	0	38
8	37	3/3	2/0	35^{+3}	Yes	Local resection	1300	600	600	0	90
9	38	3/2	1/0	35^{+2}	Yes	Local resection	2500	600	600	0	90
10	30	2/3	2/0	33^{+5d}	No	Hysterectomy	6000	3000	1500	600	145
11	39	3/1	1/0	33^{+4}	Yes	Hysterectomy	2000	600	600	300	65
12	39	1/2	1/0	34^{+3}	Yes	Hysterectomy	16 000	7500	4500	1800	205
13	32	3/1[a]	0/1[b]	34^{+1}	Yes	Local resection	2500	600	0	0	60
14	32	2/1[a]	1/0	33^{+1}	Yes	Local resection	3500[f]	2250	1000	350	75
15	39	2/1	1/1[c]	30^{+1d}	No	Hysterectomy	450	250	0	0	110
16	35	4/2	1/0	33^{+4}	Yes	Local resection	6000	2000	1890	200	100
17	34	2/1	1/2[c]	33^{+4}	Yes	Local resection	2340	1500	600	0	97
Mean	34.9	3/2	1/0	33^{+4}	–	–	4050	1780	1120	400	100
Median	34	3/2	1/0	33^{+6}	–	–	2500	900	600	70	90

Prophylactic balloon occlusion of the internal iliac arteries as part of a multidisciplinary algorithm allowed for a safe management of all cases in our consecutive series of 17 women with placenta percreta. However, intraoperative blood loss and transfusion requirements were significant. We have therefore decided to modify our multidisciplinary algorithm to include balloon occlusion of the common iliac arteries rather than the internal iliac arteries.

Figure 1. Injection of contrast media in the right common iliac artery, proximal to the inflated occlusion balloon in the right internal iliac artery, passes through collaterals from the right external iliac artery to the right internal iliac artery and the placenta. The right ovarian artery is seen.

SB Kanuni Sultan Süleyman EAH
1 Mart 2012 -30 Mart 2014

YAŞ	HAFTA	P. PREVİA	P. AKRETA	P AKRETA -	HİSTEREKTOMİ +	HİSTEREKTOMİ -
32		207	124 (%60)	83 (%40)		
		207			54 (%26)	153 (%74)

P AKRETA	HİSTEREKTOMİ +	HİSTEREKTOMİ -
124	54 (%43,5)	70 (%56,5)
		Sütur 60 Sütur+Bakri 9 Lokal rezeksiyon 1

Histerektomi (-)	PA toplam	PA -
153	70 (%45.7)	83 (54,3)

2 RELAP:
Histerektomi, Bakri

Histerektomi	Ort yaş	PP	Pİ	PA	toplam
54	32,1	**26 (%48)**	14 (%26)	14 (%26)	54 (%100)

Histerektomi	YBÜ	PL ayırma denemesi	Relap	Ort ES tr	Mesane komp	Yara yeri inf	Cuff hematom
54	31 (%57,4)	11 (%20,3)	2	**4 Ü**	1 (%18,5)	1	1

PA dışı histerektomi sayısı 10
Toplam histerektomi 64

PA histerektomi 54 **(%84,3)**

ÖNERİLER

- İlk trimesterde aşağı yerleşimli gebelikler, SSG'ne dikkat
- Prenatal tanı, morbidite-mortaliteyi azaltmada önemli
- Gebeyi doğum için erken dönemde tersiyer merkeze yönlendir
- Gebeye tedavi seçenekleri hakkında ayrıntılı bilgi ver, onam al

- **Önerilen tedavi Histerektomi**
- **Seçilmiş olgularda konservatif tedaviler**

- **Histerektominin de zor bir op olduğu unutulmamalı**

KANUNİ SULTAN SÜLEYMAN EAH PERİNATOLOJİ KLİNİĞİ

- Ocak 2005 – Aralık 2010 Bakırköy Doğumevi
  - 229 previa olgusunda **18 insersiyon anomlisi**
- Mart 2012 – Ocak 2014 KSS Perinatoloji
  - 121 plasenta previa olgusu
  - **42 histerektomi**

Yaş	32,2 (21 – 40) yıl
Sezaryen Öyküsü	
Eski C/S	15 (%35,7)
Eski 2 C/S	17 (%40,5)
Eski 3 C/S	10 (%23,8)
Doğumda gebelik haftası	36,09 hafta
Prenatal Tanı	
Evet	32 (%76,2)
Hayır	10 (%23,8)
Yoğun bakım gereksinimi	23 (%54,8)
Hastanede kalış süresi	5,9 (3 – 19) gün
Ortalama transfüzyon miktarı	4,38 (0 – 16) ünite
Komplikasyon	
Yok	31 (%73,8)
Kaf hematomu	1 (%2,4)
İleus	1 (%2,4)
Mesane yaralanması	7 (%16,7)
Yara yeri enfeksiyonu	1 (%2,4)
Relaparatomi	1 (%2,4)
Hipogastrik arter ligasyonu	5 (%11,9)
Operasyon süresi	117,3 (60 – 283) dakika
Patoloji	
İnsersiyon anomalisi yok	1
Akreta	41

DOKTORLARIMIZ

Doç Dr Halil Aslan
Doç Dr Alev A. Aydın
Doç Dr Ali Gedikbaşı
Doç Dr Gökhan Yıldırım
Uz Dr İbrahim Polat
Uz Dr Deniz Açar
Uz Dr Ali Ekiz
Uz Dr Başak Kaya
Uz Dr Salim Sezer

SEKRETERLERİMİZ
Beste Aytuğ
Gaye Özsüer
Nurşen Özgünay

HEMŞİRELERİMİZ

Sabiha Özsağ
Gülnaz Sağbaş
Bayise U. Durmuş
Özlem Günay Ulu
Gülay Kaya
Edanur Söğüt
Melis Kutlu
Neriman Er
Berna Zeybek
Asiye D. Şahin

BENİ DİNLEDİĞİNİZ İÇİN TEŞEKKÜR EDERİM

DR İBRAHIM POLAT